The Injury Mechanism of Achilles Tendon Rupture in Professional Athletes

A Video Analysis Study

Ali Yüce, MD*
Mustafa Yerli, MD*
Abdulhamit Misir, MD†

Background: In professional athletes, Achilles tendon ruptures are devastating injuries, often resulting in season loss or decreased return to sports level. We aimed to perform a comprehensive video analysis to describe the mechanisms of Achilles tendon rupture as well as body posture in professional athletes. We hypothesized that Achilles tendon ruptures in professional athletes develop with a specific injury mechanism and that body posture at the time of injury varies by sport.

Methods: Of 114 identified Achilles tendon ruptures that occurred in professional athletes between 1970 and 2020, 42 with adequate video data were analyzed for injury mechanism, body posture, and player and sport characteristics by three independent reviewers.

Results: Mean ± SD age of the 42 athletes (41 men and 1 woman) was 28.4 ± 4.26 years. Eighteen athletes played basketball (42.9%), 14 football (33.3%), five soccer (11.9%), three baseball (7.1%), and two rugby (4.8%). Thirty-five patients (83.3%) had noncontact injuries. The most frequent months of injury were January (16.7%) and October (14.3%). During Achilles tendon rupture, the ankle was in dorsiflexion, the body was bent forward, the knee and hip were in extension, and the foot was in a neutral position. Most injuries occurred during take-off/acceleration (40.5%) or stop and turn (38.5%) maneuvers.

Conclusions: In professional athletes, the Achilles tendon most often ruptures during take-off/acceleration. The most common position during rupture is the trunk in flexion, the knee and hip in extension, and the ankle in dorsiflexion. This information can guide professional athletes in terms of physical therapy techniques, including neuromuscular training, proprioception, and balance training specific to preventing Achilles tendon rupture. (J Am Podiatr Med Assoc 114(3), 2024; doi:10.7547/21-196)

Acute rupture of the Achilles tendon is one of the most common tendon injuries in the adult population, ranging from seven to 40 per 100,000 people per year.[1] It may account for up to 40% of all tendon ruptures that undergo surgery.[2] It has been shown that most Achilles injuries (~82%) occur during sports and recreational activities. This is thought to be mainly due to the sport exerting an increased mechanical load on the Achilles tendon.[3]

In professional athletes, Achilles tendon ruptures are devastating injuries, often resulting in season loss or decreased return to sports level. Sometimes, the athlete's career may end. Moreover, professional athletes often experience Achilles tendon ruptures earlier than amateur athletes due to the increased physical demands of elite athletes. Regardless of the intervention, these injuries can change the course of a career. For that reason, it is important to understand how they occur and how they can be prevented.[4]

There is limited evidence in the literature describing the mechanism of Achilles tendon rupture. Determination of this mechanism will help rehabilitation and injury prevention strategies.[4,5] Video analysis is widely used in many sports, both at the university level and at the professional level, to better understand the mechanisms of various injuries,

*Department of Orthopedic and Traumatology, Prof. Dr. Cemil Taşcıoğlu City Hospital, Istanbul, Turkey.

†Department of Orthopedic and Traumatology, Göztepe Medical Park, İstanbul, Turkey.

Corresponding author: Mustafa Yerli, MD, Department of Orthopedic and Traumatology, Prof. Dr. Cemil Tascioglu City Hospital, Istanbul, Turkey. (E-mail: mustafayerli199@gmail.com)

including ankle sprains and anterior cruciate ligament injuries.[4] There are few studies in the literature about video analysis of Achilles tendon rupture that include nonprofessional athletes or in which a single branch of sport was included with a small number of participants.[4-6]

We aimed to perform a comprehensive video analysis to describe the mechanisms of Achilles tendon injuries as well as body posture in professional athletes. We hypothesized that Achilles tendon rupture in professional athletes develops with a specific injury mechanism and that body posture at the time of injury varies in different sports.

Materials and Methods

This study was an observational retrospective study. With the help of an up-to-date search engine (Google), on August 2, 2021, 114 injuries were identified that occurred between 1970 and 2020 by searching the Internet in the English language; using public data from Achilles tendon detachments, injury reports, press releases, and player profiles in elite athletes; and all of the authors approved.[7-10] Injury videos of the identified athletes and the sports competition where the injury took place were scanned on social media platforms (YouTube, Twitter, Facebook, Dailymotion). Achilles tendon injury videos of 48 athletes were accessed. Inclusion criteria were that the Achilles tendon rupture and torn Achilles tendon were verified on public media platforms; the image at the time of injury included the foot, ankle, knee, hip, and entire body; and the video had an image quality that could detect the mentioned body parts. Exclusion criteria were not verifying the athlete's injury and professional status, insufficient image, insufficient video quality, and injuries whose accuracy was not proved. Two of these 48 videos were excluded because the foot position could not be seen clearly, and four were excluded because the image quality was too poor to determine the positions. Acute Achilles tendon injury videos of the remaining 42 professional athletes were included in the study. Player data and statistics (age, sex, year of injury, month of injury, season loss, career termination, and game numbers) were collected using public databases.[7-12] Ethics committee approval was not obtained because the data on the public platform were used. This method has been used in recent studies.[13,14]

The mechanism of injury was analyzed in two categories: noncontact and contact. Noncontact injury is defined as an injury that occurs without any contact (to the ankle or at any other level) before or during the injury. Contact injuries are divided into direct and indirect: indirect contact injury is defined as being hit, pulled, or pushed from another part of the body rather than direct contact with the injured ankle, whereas direct contact injury is defined as a direct hit to the ankle area.

Video analysis software was not used to examine any part of the video. Because the videos were not standard, it made it impossible to view the athlete from the true coronal or true sagittal plane. Angular measurements may not be accurate if coronal and sagittal plane images cannot be obtained in all videos. It may give incorrect information. For this reason, angle measurement was not performed on the program. Therefore, quantitative measurements were not performed. The videos were viewed at a speed of 0.25 slower. Due to the nature of Achilles tendon ruptures, we examined the videos for the presence of contact, game activity at the time of injury (take-off/acceleration, jump landing, jump, stop/rotation), body position (neutral, flexion, extension), body tilt (ipsilateral, contralateral), body rotation (ipsilateral, contralateral), coronal hip position (neutral, abduction, adduction), sagittal hip position (neutral, flexion, extension), hip rotation (neutral, internal, external), sagittal knee position (flexion, extension), coronal knee position (neutral, varus, valgus), ankle position (neutral, dorsiflexion, plantarflexion), hindfoot position (neutral, varus, valgus), and foot position (neutral, pronation, supination). The moment of injury was determined by the three of us watching the video together. The timing of the moment of injury in the video was determined by determining the moment of contraction of the plantar flexor muscle at the time of injury (if visible), the facial expression of the athlete, the first reaction to the injury, and the beginning of the abnormal change in activity. Then, these videos were evaluated blindly by all three of us. These three evaluators had no previous experience in biomechanical evaluation or video analysis. Previous studies were evaluated in the literature, and all three of us were informed about how to do the video analysis before the study.[4,14] These data were analyzed statistically, and intraobserver and interobserver agreement was evaluated.

Statistical Analysis

We investigated intraobserver and interobserver agreement with the Fleiss kappa (κ) statistic for categorical data (sports activity and body position). The interobserver agreement percentages were

Table 1. Number of Games Played and Season Losses in the First Season After Injury and Recovery of Athletes

	Games			
	Season Before Injury	Season of the Injury	Season After Injury	Season Loss
Mean ± SD	41.22 ± 32.89	28.90 ± 32.60	25.85 ± 29.23	0.24 ± 0.43
Median	33	20	16	0
IQR (25–75)	16.0–68.50	7.50–37.00	7.50–29.50	0–0.50

Abbreviation: IQR, interquartile range.

calculated by dividing the number of occasions of complete agreement by the total number of occasions. It was interpreted as follows: less than 0.00, poor agreement; 0.00 to 0.20, slight agreement; 0.21 to 0.40, fair agreement; 0.41 to 0.60, moderate agreement; 0.61 to 0.80, substantial agreement; and 0.81 to 1.00, almost perfect agreement. Statistical significance was set at $P < .05$. A statistical software program (IBM SPSS Statistics for Windows, Version 23.0; IBM Corp, Armonk, New York) was used in the statistical analyses.

Results

There was significant intra- ($k > 0.864$; $P < 0.001$) and inter-observer ($k > 0.815$; $P < 0.001$) reliability as a result of Fleiss kappa analysis among the three observers regarding the categorical variable. The mean ± SD age of the 42 athletes (41 men and 1 woman) included in the study was 28.4 ± 4.26 years. The right side was injured in 23 patients (54.8%), and the left side was injured in 19 patients (45.2%). The distribution of the athletes was 18 basketball (42.9%), 14 football (33.3%), five soccer (11.9%), three baseball (7.1%), and two rugby (4.8%) players. In 35 patients (83.3%), there was no contact in the injury. Four of the contact injuries (three indirect, one direct) occurred in football players and three (all indirect) in basketball players. The most frequent months of injury were January (16.7%) and October (14.3%). The number of games played in the season before the injury, in the season in which the injury occurred, and in the season after the injury are summarized in Table 1.

The game activities at the time of injury are summarized in Table 2, and the features of the video analysis regarding the injury mechanism are summarized in Table 3.

Basketball

In 18 basketball players, the ruptured Achilles tendon occurred by indirect contact mechanisms in only three cases. In 12 players, the tendon was ruptured after receiving the ball or while performing a sudden take-off/acceleration maneuver to run after the ball (n = 6) or when suddenly decelerated and changing direction (n = 6). For this reason, the classic rupture position in these athletes was with the trunk in flexion, the hip and knee in extension, and the ankle in dorsiflexion. In this body position, ready to leap forward to perform a rapid take-off maneuver, the tendon was ruptured by the contraction of the gastrocnemius for take-off. Fewer injuries occurred in the foot that first stepped on the ground during jumping (n = 2) or landing (n = 4). In contact injuries, tendon rupture occurred on the side of the athlete in contact with the ground, whose balance was disturbed during jumping (n = 1) or landing (n = 2).

Football

Of the 14 players, six had ruptured their tendon while taking off from a standing position or during acceleration, six during stopping and changing direction while running, and two in landing after rising to the ball in the air. In two cases, the athletes' balance was disturbed by the contact of the opponent during the competition while his tendon was rupturing; in one athlete, rupture occurred after the ankle injured during running by direct contact and was caught by the opponent and the movement was cut off. In these players, there were differences from basketball in the body position during the injury. Many of the NFL players were hip flexed at the time of rupture. On the other hand, in 50% of the players, the knee is flexed early; 50% of them were in extension.

Table 2. Game Activities at the Time of Injury

Activity	Patients (No. [%]) (N = 42)
Take-off/acceleration	17 (40.5)
Stop/rotate	16 (38.1)
Landing	7 (16.7)
Jump	2 (4.8)

Table 3. Positions and Body Parts According to the Video Analysis

Position	Position of Movement Relative to Planes	Patients (No. [%]) (N = 42)
Trunk position	Neutral	0
	Flexion	31 (73.8)
	Extension	11 (26.2)
Trunk tilt	Neutral	35 (83.3)
	Ipsilateral	5 (11.9)
	Contralateral	2 (4.8)
Trunk rotation	Neutral	33 (78.6)
	Ipsilateral	3 (7.1)
	Contralateral	6 (14.3)
Hip position (sagittal)	Neutral	0
	Flexion	16 (38.1)
	Extension	26 (61.9)
Hip position (coronal)	Neutral	37 (88.1)
	Abduction	4 (9.5)
	Adduction	1 (2.4)
Hip rotation	Neutral	41 (97.6)
	Internal	0
	External	1 (2.4)
Knee position (sagittal)	Flexion	19 (45.2)
	Extension	23 (54.8)
Knee position (coronal)	Neutral	40 (95.2)
	Varus	0
	Valgus	2 (4.8)
Ankle position	Neutral	2 (4.8)
	Plantarflexion	10 (23.8)
	Dorsiflexion	30 (71.4)
Hindfoot position	Neutral	34 (81.0)
	Varus	5 (11.9)
	Valgus	3 (7.1)
Foot position	Neutral	32 (76.2)
	Supination	3 (7.1)
	Pronation	7 (16.7)

Soccer

Tendon rupture occurred in two players who made the maneuver to hit the ball while in motion and in three athletes during the maneuver to stop or change direction while on the move. Unlike basketball players, four of five athletes had knee flexion at the moment of rupture.

Rugby

One of the two rugby players had a tendon rupture during acceleration after taking the ball; the other was observed during the landing.

Baseball

Both athletes had ruptured the tendon while running after the ball. One tear occurred at the time of first take-off, and the other during acceleration after take-off.

Discussion

The most important findings of this study were that during the Achilles tendon rupture, the ankle was in the dorsiflexion position while the body was bent forward, the knee and hip were in extension, and the foot was in a neutral position (Fig. 1). In 83.3% of the patients, there was no contact in the injury. Most injuries occurred during take-off/acceleration (40.5%) or stop and turn (38.5%) maneuvers.

Achilles tendon rupture usually leads to long-term functional deficits despite improved treatment and rehabilitation protocols.[15] Besides the time lost for recovery, athletes returning after an Achilles injury often fail to perform at their previous level.[3] More than 30% of professional athletes with Achilles tendon rupture cannot return to sports.[1,16] A better understanding of the factors associated with increased risk of Achilles injury and the mechanism of injury may help elucidate prevention strategies. It can enable athletes and their physicians to better understand the potential impact of injury on the athlete's career.[3,4] There are currently no definitive guidelines or evidence-based treatment programs for the prevention of Achilles tendon injuries. Therefore, variability in prevention approaches is likely among sports medicine professionals.[4] The lack of solid evidence to prevent effective injury such as Achilles tendon ruptures in athletes indicates that future studies are needed on prevention techniques and programs specific to Achilles tendon injury.[4] The present study is valuable because it is the first video analysis study aimed at defining the injury mechanism of Achilles tendon ruptures, which concerns professional athletes and different sports branches.

In two other studies on video analysis of Achilles tendon rupture, similar positions were defined except for the knee joint.[4,5] Whereas Lemme et al[4] stated that the knee was in slight flexion during the rupture of the tendon, O'Neill et al[5] stated that the knee was in extension. In the present study, the knee was most frequently in extension. However, the rate of cases with knee extension was 54.8%, and the rate of cases with flexion was 45.2%. This difference in the study by Lemme et al[4] may be the result of the inclusion of only basketball players and the small group consisting of only 12 patients. Also, theoretically, extension of the knee with the foot in dorsiflexion will result in maximum tension

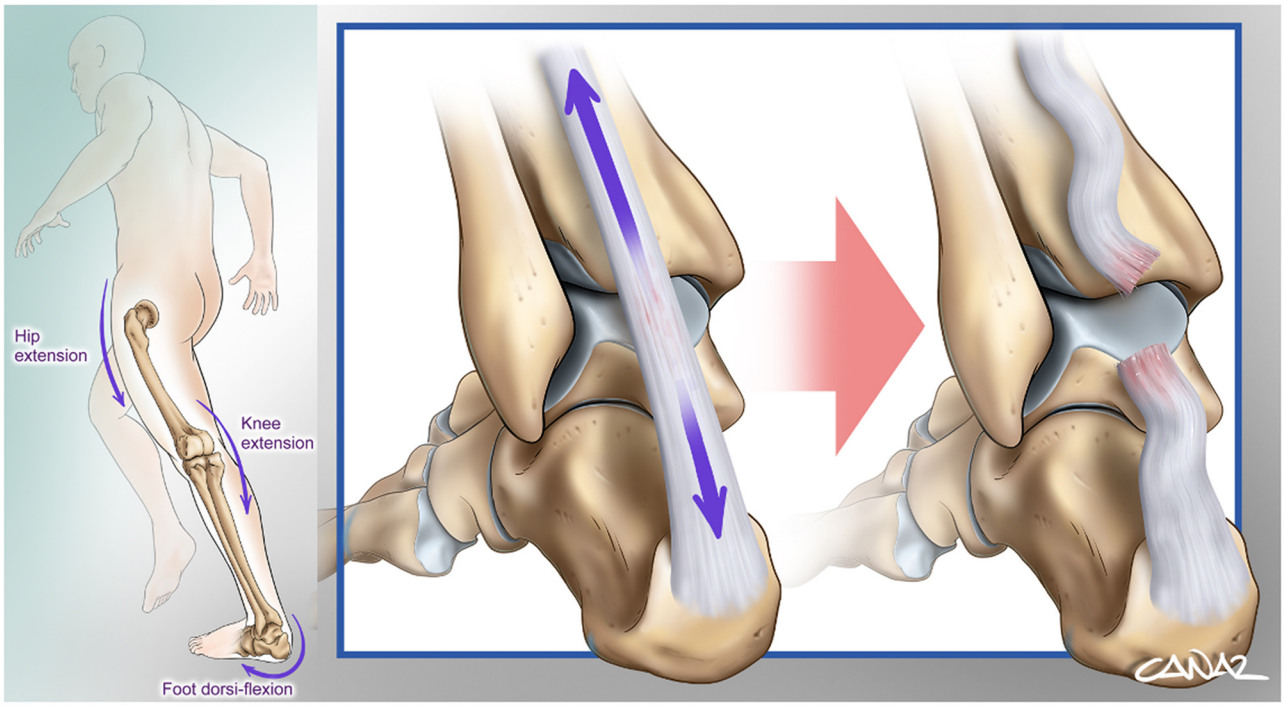

Figure 1. Illustration of the body position at the time of rupture of the Achilles tendon. Used with permission from © CC Medical Arts.

in the gastrocnemius. This fact could explain the knee extension during Achilles tendon rupture.

On the other hand, in the present study, minimal hip flexion position at the time of rupture was the most common in NFL players. In addition, half of the athletes had the knee flexed slightly, and the other half were in extension. Likewise, the rate of knee flexion was high in soccer players. In the present observations, in a few close-up basketball videos, the foot slipped back a little on the floor and the knee and hip were extended. External factors such as shoe traction and floor friction may modify sports injury risk, making the athlete even more susceptible to injury.[17,18] Although not certain, the difference in the most common position of the knee and hip during Achilles tendon rupture in basketball may be related to the different physical characteristics of the court floor than the grass surface.

Acute Achilles tendon ruptures are conventionally produced with a single powerful load stroke (eg, a sudden or severe ankle dorsiflexion move). Moreover, an acceleration-deceleration mechanism has been reported in up to 90% of sports-related Achilles tendon ruptures.[19] Take-off motion while standing is the most common cause of Achilles tendon ruptures.[4] Just before take-off, as the foot is on the ground in dorsiflexion, the calf muscles undergo eccentric contraction to prevent the foot on the ground from falling. Meanwhile, the energy is stored in the Achilles tendon as elastic energy, which ultimately helps repulsion. As the triceps surae contracts vigorously, the foot is plantarflexed and allows take-off. Meanwhile, it has been shown that the force transmitted from the Achilles tendon approaches six to eight times the body weight of the person, potentially exceeding the final strength of the tendon and causing rupture.[4] This explains the rupture mechanism of the tendon during take-off or acceleration, which is the most common injury activity.

On the other hand, during the maneuver of an accelerated athlete, while the foot is in contact with the ground, he will lock his knee and hip in extension and try to slow down or stop with the force from the friction force of the ground. In the meantime, the force that increases with the effect of acceleration and is transferred to the foot will force the ankle to dorsiflex. This force transferred to the ankle will have to be compensated by the Achilles tendon. This may explain the second most common cause of tendon rupture during the stopping/turning maneuver.

In a video analysis of anterior cruciate ligament injuries, Della Villa et al[14] cited the lack of research detailing the biomechanical factors of anterior cruciate ligament injuries in football, particularly regarding

the role of the trunk. They also evaluated the position of the player's trunk in anterior cruciate ligament injuries. And they mentioned that the displacement of the body's position and the center of mass could increase the load on the anterior cruciate ligament. In the present study, the fact that the trunk is mostly in flexion can be interpreted as the transfer of the center of gravity to the front during the take-off/acceleration maneuver, contributing to the acceleration of take-off by transferring the center of gravity to the front, or the movement of the backward body with the flexion of the center of gravity to the braking movement by transferring it to the front when braking with the foot.

Playing basketball is the most common cause of sports-related Achilles tendon ruptures.[1,4] Considering that basketball is a sport associated with attacks that start and end within seconds, maneuvers such as sudden take-off, stopping, accelerating, and turning are common. This explains why Achilles tendon ruptures are most common in basketball players.

Sports-related Achilles tendon rupture is most common in the winter months.[20] In the present study, the most injuries occurred in January. This situation may be related to the seasons in which the sport is played. It may also vary according to the sport examined. In this study, the most common Achilles tendon injuries were in basketball players. Most of these players are NBA players; NBA games coincide with the winter season. This may result in injuries occurring most frequently during the winter months.

Achilles tendon injuries often occur without contact.[3-5] Male patients aged 20 to 39 years who are engaged in sports are at the greatest risk for injuries.[1] The average age in the present study and most noncontact injuries supported this situation.

Measures such as prophylactic bracing, rule changes for injury-causing maneuvers, and sport-specific aerobic and anaerobic conditioning, strengthening, and neuromuscular control exercises can be taken to prevent sports injuries.[21,22] Rule changes and a brace can be preventive in contact mechanism injuries.[22,23] However, Achilles tendon injuries occur by noncontact mechanisms.[3,5] For this reason, sport-specific aerobic and anaerobic conditioning, strengthening, and neuromuscular control exercises may be beneficial in preventing Achilles tendon injuries.

This study had several limitations. Factors such as the type of surgical treatment of athletes, the characteristics of tendon rupture, the surgical treatment method applied, and the duration and characteristics of the postoperative rehabilitation are unknown. In addition, the risk factors for these athletes that cause Achilles tendon rupture are unknown. Also, because the injury data are obtained from public records, they may not be 100% accurate, and we may not be able to verify that every athlete who is assessed as an Achilles tendon rupture during the study period experienced an Achilles tendon rupture. However, similar methods have been used and accepted in many previous studies.[4,24-26] Another shortcoming can be listed as the limitations in video analysis. Because the videos are obtained from different platforms, the video quality, camera angles, distance at which the images were taken, and number of views obtained from different angles were not the same. Due to the lack of standardization, joint angles based on rupture could not be measured on a video program; it could not be analyzed quantitatively by putting it into numerical values. Because only the positions at the time of tendon rupture were defined, it could be evaluated qualitatively. A limitation was that we had no previous video analytics experience. However, the intraobserver and interobserver compatibility are almost perfect and can be accepted as an indication that this video analysis was performed correctly. However, despite the shortcomings, it provides information as one of the first studies with video analysis of the body positions and activities of the athletes in Achilles tendon injury, which includes only professional athletes and different types of sports. (Since acceptance of this article, two additional studies have been published in the literature.)[27,28]

Conclusions

In professional athletes, the Achilles tendon most often ruptures during take-off or acceleration. The most common position during rupture is the trunk in flexion, the knee and hip in extension, and the ankle in dorsiflexion. This information can be a guide for professional athletes in terms of physical therapy techniques, including neuromuscular training, proprioception, and balance training specific to preventing Achilles tendon rupture.

Acknowledgment: Gökhan Canaz, MD, for the illustration of the body position at the moment of rupture of the Achilles tendon.
Financial Disclosure: None reported.
Conflict of Interest: None reported.

References

1. Lemme NJ, Li NY, DeFroda SF, et al: Epidemiology of Achilles tendon ruptures in the United States: athletic

and nonathletic injuries from 2012 to 2016. Orthop J Sports Med **6:** 2325967118808238, 2018.
2. Esenyel CZ, Tekin C, Cakar M, et al: Surgical treatment of the neglected Achilles tendon rupture with Hyalonect. JAPMA **104:** 434, 2014.
3. Chan JJ, Chen KK, Sarker S, et al: Epidemiology of Achilles tendon injuries in collegiate level athletes in the United States. Int Orthop **44:** 585, 2020.
4. Lemme NJ, Li NY, Kleiner JE, et al: Epidemiology and video analysis of Achilles tendon ruptures in the National Basketball Association. Am J Sports Med **47:** 2360, 2019.
5. O'Neill S, Gibson N, Regan D, et al: A systematic video analysis of the mechanism of injury of Achilles tendon ruptures. Br J Sports Med **55** (suppl 1): A12.2, 2021.
6. Loturco I, De la Fuente C, Bishop C, et al: Video-based biomechanical analysis of an unexpected Achilles tendon rupture in an Olympic sprinter. J Biomech **117:** 110246, 2021.
7. Basketball Reference Web site. Available at: https://www.basketball-reference.com/. Accessed June 1, 2018.
8. ESPN Web site. Available at: https://www.espn.com/. Accessed January 1, 2021.
9. Google Web site. Available at: https://www.google.com. Accessed January 1, 2021.
10. NFL Web site. Available at: https://www.nfl.com. Accessed January 1, 2021.
11. TFF Web site. Available at: https://www.tff.org. Accessed January 1, 2021.
12. Transfermarkt Web site. Available at: https://www.transfermarkt.com.tr. Accessed January 1, 2021.
13. Locks R, Utsunomiya H, Briggs KK, et al: Return to play after hip arthroscopic surgery for femoroacetabular impingement in professional soccer players. Am J Sports Med **46:** 273, 2018.
14. Della Villa F, Buckthorpe M, Grassi A, et al: Systematic video analysis of ACL injuries in professional male football (soccer): injury mechanisms, situational patterns and biomechanics study on 134 consecutive cases. Br J Sports Med **54:** 1423, 2020.
15. Baxter JR, Hullfish TJ, Chao W: Functional deficits may be explained by plantarflexor remodeling following Achilles tendon rupture repair: preliminary findings. J Biomech **79:** 238, 2018.
16. Parekh SG, Wray WH III, Brimmo O, et al: Epidemiology and outcomes of Achilles tendon ruptures in the National Football League. Foot Ankle Spec **2:** 283, 2009.
17. Bahr R, Krosshaug T: Understanding injury mechanisms: a key component of preventing injuries in sport. Br J Sports Med **39:** 324, 2005.
18. Pasanen K, Parkkari J, Rossi L, et al: Artificial playing surface increases the injury risk in pivoting indoor sports: a prospective one-season follow-up study in Finnish female floorball. Br J Sports Med **42:** 194, 2008.
19. Tarantino D, Palermi S, Sirico F, et al: Achilles tendon rupture: mechanisms of injury, principles of rehabilitation and return to play. J Funct Morphol Kinesiol **5:** 95, 2020.
20. Saarensilta IA, Edman G, Ackermann PW: Achilles tendon ruptures during summer show the lowest incidence, but exhibit an increased risk of re-rupture. Knee Surg Sports Traumatol Arthrosc **28:** 3978, 2020.
21. Grant JA, Bedi A, Kurz J, et al: Incidence and injury characteristics of medial collateral ligament injuries in male collegiate ice hockey players. Sports Health **5:** 270, 2013.
22. Chen L, Kim PD, Ahmad CS, et al: Medial collateral ligament injuries of the knee: current treatment concepts. Curr Rev Musculoskelet Med **1:** 108, 2008.
23. Najibi S, Albright JP: The use of knee braces, part 1: prophylactic knee braces in contact sports. Am J Sports Med **33:** 602, 2005.
24. Johnston JT, Mandelbaum BR, Schub D, et al: Video analysis of anterior cruciate ligament tears in professional American football athletes. Am J Sports Med **46:** 862, 2018.
25. Minhas SV, Kester BS, Larkin KE, et al: The effect of an orthopaedic surgical procedure in the National Basketball Association. Am J Sports Med **44:** 1056, 2016.
26. Trofa DP, Miller JC, Jang ES, et al: Professional athletes' return to play and performance after operative repair of an Achilles tendon rupture. Am J Sports Med **45:** 2864, 2017.
27. Della Villa F, Buckthorpe M, Tosarelli F, et al: Video analysis of Achilles tendon rupture in male professional football (soccer) players: injury mechanisms, patterns and biomechanics. BMJ Open Sport Exerc Med **8:** e001419, 2022.
28. Hoenig T, Gronwald T, Hollander K, et al: Video analysis of Achilles tendon ruptures in professional male football (soccer) reveals underlying injury patterns and provides strategies for injury prevention. Knee Surg Sports Traumatol Arthrosc **31:** 2236, 2023.